

How to Perform the Digital Venogram

Amy Rucker, DVM; Ric F. Redden, DVM; Elizabeth G. Arthur, DVM;
Shannon K. Reed, DVM; Bradley W. Hill, DVM; Elaine M. Dziuban, DVM; and
Daniel C. Renfro, DVM

The digital venogram is a diagnostic procedure using contrast radiography to assess the vasculature of the foot. Authors' addresses: Midwest Equine, PO Box 30520, Columbia, MO 65205 (Rucker); International Equine Podiatry Center, PO Box 507, Versailles, KY 40383 (Redden); Chesapeake Veterinary Referral Surgery, 808 Bestgate Road, Annapolis, MD 21401 (Arthur); Veterinary Medicine, Department of Clinical Sciences, Oregon State University, Corvallis, OR 97331 (Reed); Merritt and Associates, 26996 North Darrell Road, Wauconda, IL 60084 (Hill); Cedar Hill Mobile Equine, 6445 Carmon Road, Gibsonville, NC 27249 (Dziuban); and Renfro Veterinary Services, 420 Wollard Boulevard, Richmond, MO 64085 (Renfro); e-mail: ruckeramy@hotmail.com (Rucker). © 2006 AAEP.

1. Introduction

The digital venogram allows assessment of vascular perfusion of the foot using contrast radiography. The technique for performing a venogram in the standing horse was developed by Drs. C. C. Pollitt and R. F. Redden in 1992 and has subsequently been published.¹⁻³ This paper will detail a refined technique.

Laminitis is defined as failure of attachment of the distal phalanx and the inner hoof wall.⁴ Pathology alters the structural integrity of the foot and compromises the vascular supply. In a study comparing vascular perfusion casts of normal versus chronic laminitic feet, it was shown that defects in submural laminar circulation, coronary perfusion, and solar circulation were worse in horses with clinically refractive laminitis.⁵ These areas can be objectively evaluated *in vivo* by the digital venogram, which indicates a correlation between loss of structural integrity, mechanical load, and compromised vasculature. Other indications include distinguishing between white line

disease and laminitis, evaluating pathology and load in the club foot and crushed heel foot, delineating margins of keratomas, and determining diagnosis when differentials for acute lameness include excessive trimming, pedal osteitis, foot abscessation, and laminitis.

2. Materials and Methods

All equipment necessary for the venogram should be gathered and placed within reach. This includes radiograph equipment, tourniquet (2.5-cm wide and 90-cm long) fashioned from car inner tube, 21-g, 1.9-cm butterfly catheter with 30.5-cm tubing,^a two 12-ml luer lock syringes each filled with 10 ml of diatrizoate sodium^b contrast (for a foot that is 12-cm wide), and mosquito hemostats.

To prepare the foot for radiographs, anesthetize the medial and lateral palmar digital nerves with mepivacaine 2%^c at the level of the proximal sesamoids. The horse should then be sedated with detomidine hydrochloride^d (0.002–0.01 mg/kg, IV). Clip and aseptically prepare the pastern in the area

NOTES



Fig. 1. Positioning for catheterization of the lateral palmar digital vein of the right forelimb.

of the palmar digital vein. Stand the horse on radiograph blocks so that the primary beam is at the level of the palmar surface of the distal phalanx, and position the radiograph machine for a lateromedial view. Apply a radiopaque dorsal wall marker.

Wrap 10.2-cm tape^e around the fetlock at the level of the sesamoids. Adhere the tourniquet to the free end of the tape on the fetlock. Tightly apply the tourniquet, taking care not to distort the skin on the pastern. Tape the tourniquet in place with several wraps of tape, and cut the tape on the caudolateral aspect of the leg, leaving the last 4 cm loosely applied.

Position yourself dorsolateral to the foot with your assistant caudal to the radiograph machine. The veterinarian places his medial shoulder against the dorsal aspect of the carpus, wraps his arm around the leg medially before palmarly, and uses that hand to inject the contrast. The catheter is placed mid-pastern in the lateral palmar digital vein (Fig. 1). The veterinarian's lateral hand places light digital pressure on the vein at the level of the needle and slightly distal. Blood should drip freely from the catheter.

The assistant attaches a syringe to the catheter, the veterinarian quickly injects the contrast, and the assistant replaces the empty syringe. As the second syringe is injected, the veterinarian uses his medial arm to gently flex the carpus, which unloads the limb, and then pushes the carpus caudally with his shoulder to load the limb. The assistant positions the first radiograph cassette, clamps the catheter tubing with a pair of hemostats, removes the syringe, and tucks the hemostat under the free end of tape at the fetlock. The veterinarian takes a plain-film lateromedial radiograph, a lateromedial radiograph with a grid, and removes the dorsal wall marker. The veterinarian positions the machine cranially and takes a 0° dorsopalmar view with a

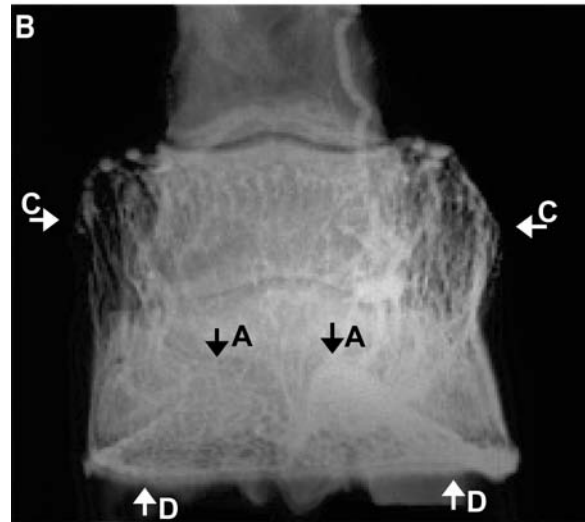
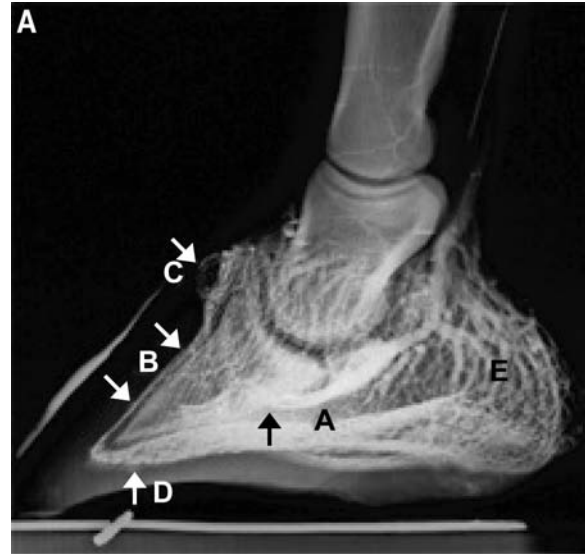

Fig. 2. (A) Lateral and (B) dorsopalmar venograms of a normal foot. Areas of interest include the (A) terminal arch of the palmar digital vessels, (B) dorsal lamellar vessels, (C) coronary plexus, (D) circumflex vessels and their dermal papillae, and (E) heel vasculature. (Courtesy of A. Rucker⁶).

grid followed by a plain-film view. At the end of the procedure, a "late" lateral view is taken. During the radiograph process, the veterinarian changes the technique settings and takes radiographs, while the assistant positions radiographic cassettes. All views should be taken within 45 s of the injection.

Remove the tourniquet, and pad the medial and lateral palmar digital veins with dry gauze squares. Remove the pressure bandage in 10–15 min.

3. Results

Injection of contrast into the lateral vein results in retrograde fill of the capillaries, arteries, and medial veins (Fig. 2).⁶ The terminal arch of the palmar digital vessels, coronary plexus, dorsal lamellar ves-

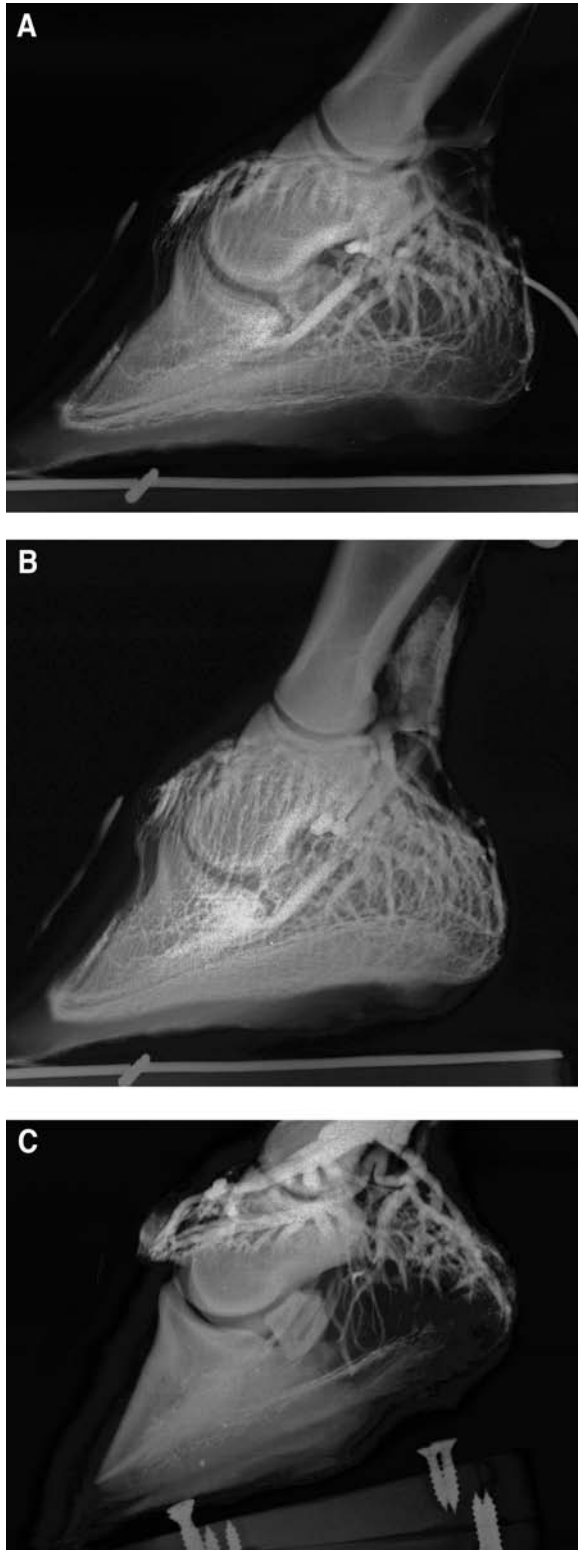

Fig. 3. (A) A 12-cm-wide Quarter Horse foot with only 10 ml of contrast injected. Gradual tapering of the vessels and areas with reduced fill such as these dorsal lamellar, coronary areas, and heel areas characterize inadequate volume of contrast. (B) The same foot after an additional 10 ml of contrast was injected. The appearance of inadequate volume should not be confused with that of the (C) classic sinker. There is minimal contrast tapering into the heel and terminal arch, but the major-

sels, circumflex vessels, and heel region are evaluated on the venogram. Their appearance is consistent in the non-pathologic foot and is repeatable over time in individual feet.^f Different radiographic techniques allow visualization of both the subtle vessels of the solar papillae as well as the more radiopaque vessels in the terminal arch. The "late" lateromedial view images the contrast as it begins diffusing into the tissue, occasionally delineating an area of pathology.

The resultant loss of structural integrity induced by laminitis allows displacement of the third phalanx within the hoof capsule. The normal venogram image is altered by the morphologic changes involving the lamellae combined with tissue-shearing forces and compression by the displaced third phalanx. Experimentally induced laminitis in 10 horses with serial venograms over 12 wk show progressive vascular changes correlating with the degree of displacement of the distal phalanx and clinical lameness.⁷ Another study compared digital venograms both from horses unaffected by laminitis and from horses diagnosed with chronic laminitis. Multiple blinded evaluators individually graded the five major regions of perfusion as normal or abnormal. Significant differences between the normal and chronically laminitic groups were identified in the coronary plexus, dorsal lamellar vessels, and circumflex vessels ($p < 0.05$ using the Fischer test).⁸ After performing >1156 venograms (including 178 on feet without clinical or radiographic evidence of laminitis) in clinical practice, the authors have found a close correlation between venographic findings, clinically and radiographically evident pathologic changes within the foot, and case progression.

4. Discussion

Laminitis is evaluated in terms of the history and degree of the lameness, physical examination, and radiographic findings.^{9,10} Disagreement exists regarding the prognostic significance of these findings.⁹⁻¹⁵ The venogram shows changes within the dermis that are not visible on plain-film radiographs. The information contributes to evaluating the duration of disease and degree of pathology within the soft tissue of the foot, assisting in the development of treatment plans and determining the prognosis for recovery. When consistent technique is performed, serial venograms document response to treatment or the lack thereof. If improper techniques are performed, valuable information is lost when evaluating images, and there is

ity of the vessels are bluntly truncated at the coronary band. This horse has no digital rotation; however, as evidenced by the venogram, it has a grave prognosis for survival because of the lack of perfusion in the foot. Note that improper technique should not be mistaken for inadequate perfusion. (Courtesy of A. Rucker⁶).

no basis for comparison of images as the case progresses. Interpretation of the venogram requires that practitioners familiarize themselves with the vascular anatomy of the foot and review multiple normal and pathologic case studies before they will become competent at differentiating between technique-induced artifacts and pathology.^{16,17}

The digital venogram is technique sensitive. Common errors begin with improper positioning of the horse, which results in uneven loading of the foot. Both feet should be locally anesthetized (not just the foot that is being studied), the radiograph blocks should be positioned to account for rotational limb deformities, the cannon bone should be vertical to the ground, and the horse's head and neck should not be pulled to one side. Reduced perfusion of the coronary band evident on the dorsopalmar view results from uneven loading of the limb. Evaluate the orientation of the long bones on the radiographs to suggest stance at the time of the venograms. Beam positioning is critical when evaluating solar papillae; the beam is centered at the palmar surface of the coffin bone and not at the center of the foot.

Traditional film systems require a soft-tissue exposure as well as a grid image with higher mAs for the vasculature within the coffin bone; this may also be necessary with digital units. Be certain to do a baseline venogram on a non-pathologic foot with a heavy sole to determine your exposure techniques as well as the capability of your equipment to evaluate subtle detail. Some computed radiography (CR) and direct digital radiography (DR) units on the market require adjustments in image processing or upgrades to a higher resolution monitor before they can show solar papillae. Resist making assumptions if poor radiographic technique obscures details.

Tourniquet failure results in an appearance of inadequate volume within the foot. The venogram image does not appear fully perfused, and vessels gradually taper and narrow as they course through the foot (Fig. 3). Tourniquet failure results from excessive volume of perineural anesthetic agent, excessive amount of tape placed on the skin, a loose first wrap of tourniquet around the fetlock, and excessive edema within the limb. Tourniquets are seldom effective when applied midcannon, and a radiograph will reveal contrast proximal to the tourniquet. When applying the tourniquet, take care not to twist the skin or apply the tourniquet in a proximal to distal direction; this distorts the skin and obscures the pastern, which makes catheterization difficult.

If you are having difficulty identifying the vein for catheterization, you may need to mark the injection site with a permanent marker or catheterize the vein before applying the tourniquet. Difficulty in catheterization results in multiple venipunctures, evident on venogram images as perivascular contrast at the site of injection, which results in a pattern of inadequate volume.

After the vein is catheterized, blood immediately flows into the tubing and begins dripping out the injection port. Do not attempt to advance the needle, because the vein is tortuous; this commonly results in multiple venipunctures. The lateral hand maintains light digital pressure over the needle to prevent vibration as the contrast is rapidly injected. Make sure to prevent catheter movement as the assistant exchanges the syringes and maintain catheter placement if the horse picks up the foot. Perivascular contrast is appreciated by a pal-

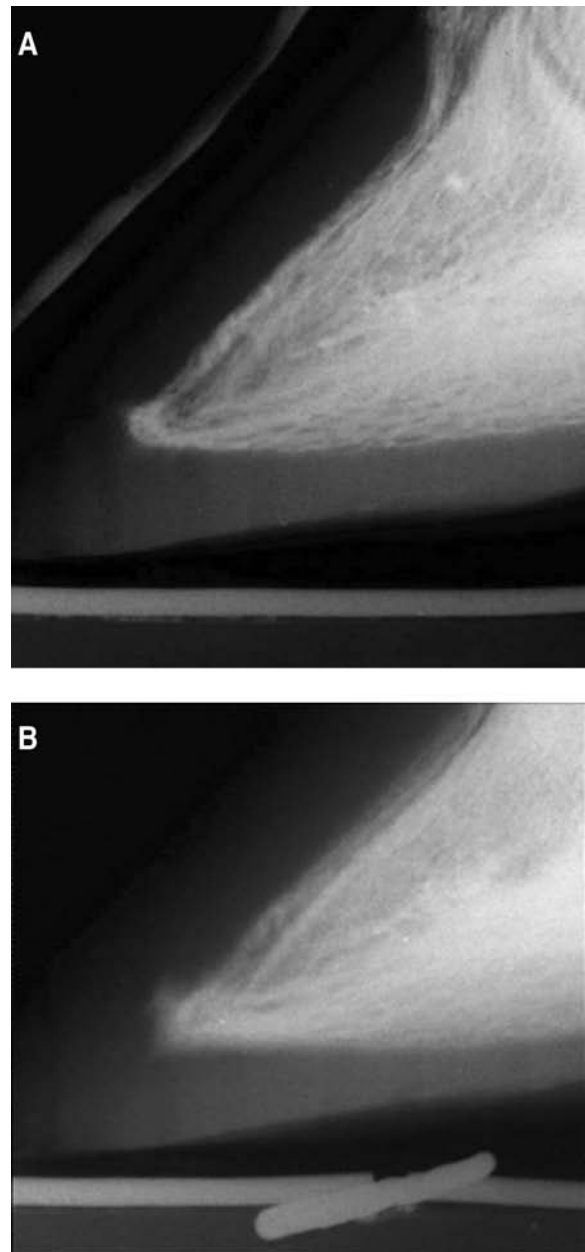


Fig. 4. All images should be taken within 45 s of contrast injection. (A) Twenty seconds after injection and (B) 120 s after injection. This artifact is evidenced by the loss of crisp margins of the vessels.

pable coolness at the injection site. If you suspect that the catheter is dislodged, discontinue pressure on the syringe plunger; a flash of blood should backflow into the catheter tubing if the catheter is still in the vein. Originally, a 65° dorsopalmar view was part of the venogram series.² We no longer perform this view, because it adds little to the amount of information obtained. As the foot is repositioned, it is easy to dislodge the catheter, which results in perivascular leakage and an inadequate volume pattern. Some practitioners use a 30-ml syringe instead of two 12-ml syringes so that they do not dislodge the catheter as the syringes are exchanged. We believe it is more important to monitor resistance as the contrast is injected, and this cannot be appreciated with a large syringe.

If the horse begins moving as you are injecting the contrast, your shoulder will feel the horse unload the weight on the leg before the foot comes off the block. Cradle the leg with your inside arm, and maintain digital pressure with your lateral hand as you continue to inject the contrast. If the horse refuses to stand on the foot, take a non-weight-bearing lateral radiograph within the time constraints. Then, replace the foot on the block, and take a second lateral radiograph so that the weight-bearing image may be compared with previous and future images. The entire procedure must be performed quickly, because the contrast is hypersomolar and rapidly diffuses into the tissue. Time delay in taking the radiographs may result in misinterpretation of perfusion (Fig. 4).

The procedure should be perfected on a normal horse, because clumsiness in technique may be detrimental to perfusion of the diseased foot. If the lateral vein is blown, attempting to catheterize the medial vein is contraindicated. Edema secondary to perivascular contrast will resolve in 24 h, but we recommend that you wait 2–3 days for the blown vein to repair before you reattempt the venogram.

In summary, the venogram is relatively inexpensive and requires only the standard radiograph equipment present in most equine hospitals. With a small amount of practice, a team of people can become proficient at performing the venogram. Vascular changes show pathology that cannot be assessed by traditional methods, aiding in the determination of diagnosis, prognosis, and treatment protocols for the diseased foot. Maximizing the amount of information obtained begins with a consistent technique when performing the procedure.

The authors would like to thank Howard Wilson for his assistance with the digital images.

References and Footnotes

1. Redden RF. The use of venograms as a diagnostic tool, in *Proceedings*. 7th Bluegrass Laminitis Symposium 1993;1–6.
2. Redden RF. A technique for performing digital venography in the standing horse. *Equine Vet Edu* 2001;5:172–178.
3. Rucker A. Key points of the digital venogram, in *Proceedings*. 16th Bluegrass Laminitis Symposium 2003;105–109.
4. Pollitt CC. Equine laminitis: a revised pathophysiology, in *Proceedings*. 45th Annual American Association of Equine Practitioners Convention 1999;188–192.
5. Hood DM, Grosenbaugh DA, Slater MR. Vascular perfusion in horses with chronic laminitis. *Equine Vet J* 1994;26:191–196.
6. Rucker A. The digital venogram. In: Floyd AE, Mansmann R, eds. *Equine podiatry: medical and surgical management of the hoof*. Philadelphia: Elsevier, 2006.
7. Baldwin G. Retrograde venous angiography (venography) of the equine digit during experimentally induced laminitis, in *Proceedings*. 3rd International Equine Conference on Laminitis and Diseases of the Foot 2005;359–360.
8. Arthur E, Rucker A. The use of digital venography for assessment of perfusion deficits in chronic laminitis, in *Proceedings*. International Equine Conference on Laminitis and Diseases of the Foot 2003;2:319.
9. Swanson TD. Clinical presentation, diagnosis, and prognosis of acute laminitis. *Vet Clin North Am [Equine Pract]* 1999;15:311–319.
10. Herthel D, Hood DM. Clinical presentation, diagnosis, and prognosis of chronic laminitis. *Vet Clin North Am [Equine Pract]* 1999;15:375–394.
11. Hunt RJ. A retrospective evaluation of laminitis in horses. *Equine Vet J* 1993;25:61–64.
12. Stick JA, Jann HW, Scott EA, et al. Pedal bone rotation as a prognostic sign in laminitis of horses. *J Am Vet Med Assoc* 1982;180:251–253.
13. Cripps PJ, Eustace RA. Factors involved in the prognosis of equine laminitis in the UK. *Equine Vet J* 1999;31:433–442.
14. Hood DM. Prognosis of chronic laminitis, in *Proceedings*. 14th Bluegrass Laminitis Symposium 2001;27–48.
15. Moyer W, Schumacher J, Schumacher J. Chronic laminitis: considerations for the owner and prevention of misunderstandings, in *Proceedings*. 46th Annual American Association of Equine Practitioners Convention 2000;59–61.
16. Rucker A. Aspects of the normal digital venogram: anatomy, parameters and variations, in *Proceedings*. 16th Bluegrass Laminitis Symposium 2003;27–32.
17. Rucker A. Interpreting venograms: normal or abnormal and artifacts that may be misinterpreted, in *Proceedings*. 16th Bluegrass Laminitis Symposium 2003;97–101.

^aAbbott Laboratories Inc., Abbott Park, IL 60064.

^bHypaque 76, Nycomed Inc., Princeton, NJ 08540.

^cPolocaine, Astra Zeneca LP, Wilmington, DE 19850.

^dDormosedan, Pfizer Animal Health, Exton, PA 19341.

^eElastikon, Johnson & Johnson, New Brunswick, NJ 08933.

^fEarl N, Wilson DA, Rucker A. Evaluation of the effects on vasculature perfusion in the equine hoof caused by corrective shoeing with a wedged heel using digital venography. Unpublished data, 2004.